

# ENDOSCOPIC GASTROCNEMIUS RECESSION (EGR) TECHNIQUE

Stephen L. Barrett, D.P.M., FACFAS  
Adjunct Professor  
Midwestern University, College of Health Sciences  
Arizona Podiatric Medicine Program

## INTRODUCTION

Equinus is probably the most unrecognized, and untreated pathological condition affecting the human lower extremity. Numerous forefoot pathological symptoms are attributed to its devastating biomechanical forces, yet there is a large segment of foot and ankle surgeons who simply do not address the condition concurrently with other surgical intervention. It is the author's opinion this relegation of equinus to the "surgical back burner" is largely due to the techniques previously available to the treating surgeon in addition to how they were trained. Essentially, prior to the advent of minimally invasive, endoscopic surgical techniques, the surgeon was left with one of several choices. First, a percutaneous Achilles tendon lengthening could be performed, which was less invasive than an open Achilles tendon lengthening, but still hampered with a long recovery period associated with the cutting of this major tendon, and an assured loss of one grade of muscle strength. Another approach would be for the surgeon to address the problematic equinus with an open Gastrocnemius recession, with something like a Vulpius or Strayer technique. These techniques are traumatic, and not suited to concurrent performance with other forefoot surgical techniques because of patient positioning on the operating room table, and the added length of intraoperative time associated with an "open" gastroc procedure. As technology and surgical techniques improve, the surgeon's job becomes easier, and the ultimate surgical outcome for the patient improves. This is indeed the case with Endoscopic Gastrocnemius Recession (EGR). Once a surgeon becomes trained in the EGR technique, he will recognize and appreciate the presence of deforming biomechanical forces from equines. In addition, the use of this technique will only improve patient outcomes, but decrease post-operative morbidity associated with other forefoot surgical procedures that many times will resolve without surgery after the equinus deformity is addressed. While a conservative philosophy in surgery is always admired, nothing can be considered truly "conservative" if only part of a patient's problem is being addressed. There is nothing conservative about surgically treating severe hallux valgus with a distal metaphyseal osteotomy, when there is a high intermetatarsal angle, the apex of the deformity is proximal, and there is severe equinus present.

## INDICATIONS:

The EGR technique is indicated for the treatment of Gastrocnemius equinus. Equinus can be attributed to different etiology and classifications. The diagnosis of equinus is straightforward and not nebulous. There is some confusion in the literature as to the definition of equinus; some sources indicate anything less than 10 degrees of dorsiflexion of the foot to the leg when the knee is fully extended, while others indicate 5 degrees, and still others talk about 0 degrees. # [1-4] Anything amounting to dorsiflexion less than 10 degrees, with the knee fully extended is pathologic, and patients demonstrating other symptomatology (most forefoot conditions) are likely suffering from the biomechanical aberrations associated with it. Equinus can be categorized into four classifications: 1.) Gastrocnemius equinus, 2.) Gastrocnemius-Soleal, 3.) Osseous Equinus, and 4.) Pseudo Equinus.

Gastrocnemius equinus is the most common type of equines, and is appropriately addressed with the EGR technique. It is imperative that the clinician ascertain the type of deformity present prior to surgical intervention. This can be determined clinically with the Silfverskiold test, and should be documented in the patient's chart. As can be seen in Figure 1, the amount of dorsiflexion is determined in the patient with the knee fully extended. The clinician should be careful to avoid mistaking dorsiflexion at the level of the midtarsal joint. This can be avoided by slightly supinating the foot, which locks the midtarsal joint, and prevents inaccurate measurement.

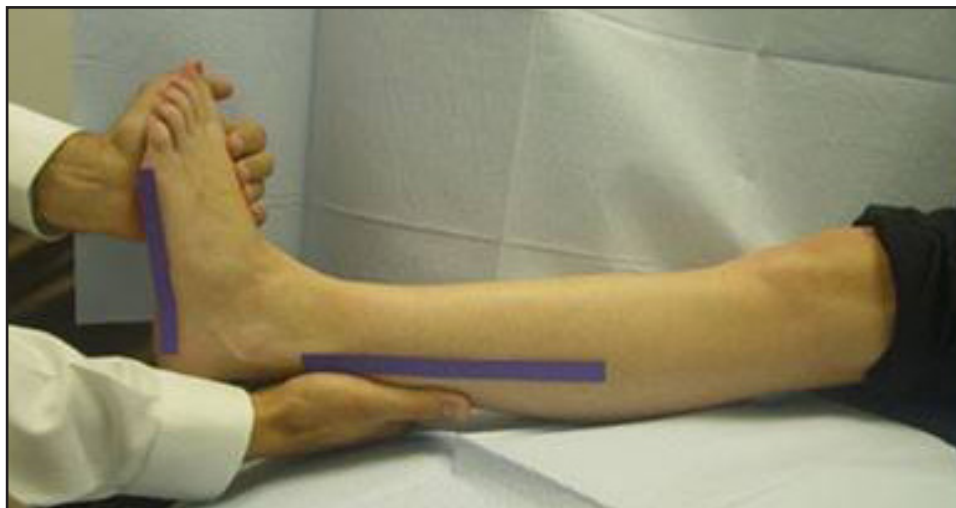

Fig 1

In Figure 2, the amount of dorsiflexion is measured with the knee flexed. If there is at least 10 degrees of dorsiflexion available after the knee is flexed, when there was a limitation of dorsiflexion with the knee extended, the clinician can be assured that the deforming force is due to muscles that cross the knee joint: the gastroc and plantaris. As the plantaris is a very small muscle, its contribution to equinus can be of little concern to the operating surgeon. This would be defined as a true Gastrocnemius equinus, and the EGR technique is indicated in this situation.

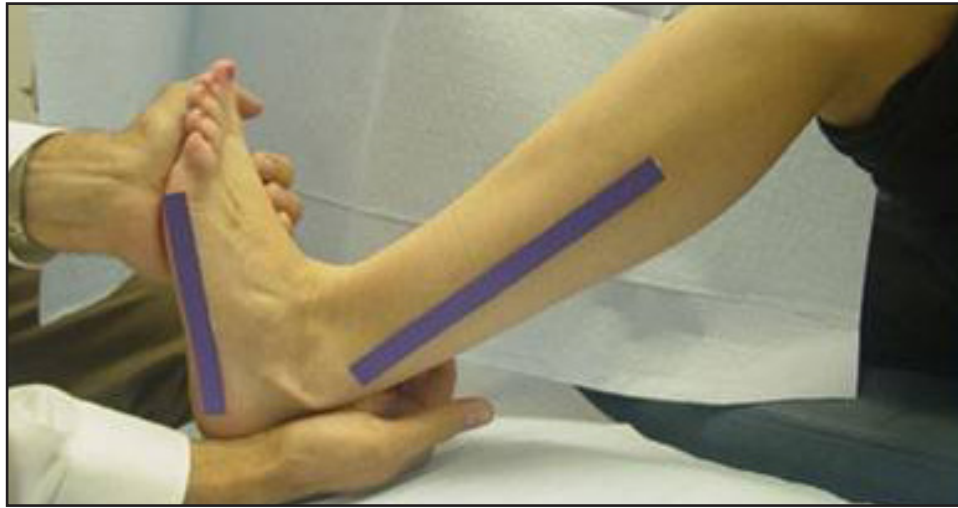

Fig 2

Gastrocnemius-Soleal equinus may be present if there is some increase in dorsiflexion when the knee is flexed, from what was available when extended, but less than 10 degrees of increase. This would indicate there could be some contribution of tightness from the soleal muscle. Any type of Gastrocnemius recession would not be ideally indicated for this type of equinus, as this type of procedure, whether open or endoscopic, does not address the soleal component of the equinus. The proper procedure in this clinical presentation would be some type of surgical intervention aimed more distally to the Achilles tendon. If upon examination, there appears to be a soleal contribution to the patient's equinus, radiographs must be taken to rule out any type of bony block. No soft tissue procedure will achieve the desired patient outcome of increasing ankle joint dorsiflexion, if there is presence of osseous equinus.

Osseous equinus, a bony block, must be ruled out in all patients undergoing any type of triceps surae surgery via radiographs. Appropriate surgical intervention for this type of surgery may include the EGR technique in conjunction with an osseous resection of the anterior talotibial impingement, but not the EGR as an isolated technique.

Pseudo equinus is also sometimes referred to as anterior equinus. In a severe cavus foot, the available amount of ankle joint dorsiflexion is decreased (used up) due to compensation for the severely declinated metatarsals. As with an osseous equinus, the EGR technique may be included as an ancillary procedure in the overall global treatment of the complex condition, but not indicated as an isolated technique.

## PRE OPERATIVE CONSIDERATIONS:

Once the clinical and biomechanical examination has confirmed the presence of a Gastrocnemius equinus, without osseous limitation, planning for the endoscopic gastroc recession can begin. Patient positioning on the operating room table is variable depending on the performance of concurrent surgical procedures. Most often the EGR can be easily performed with the patient supine on the operating table. If the patient has to be prone, there may be anesthetic considerations: This may cause some concern on the behalf of anesthesia, and if this is the surgeon's plan, then there should be a discussion with the anesthesia team about ASA classification, and the safety of the patient with this type of positioning. As with any surgical procedure, informed consent is mandatory with this technique. The patient must be informed that the greatest and most likely complication with this technique is damage, or transection of the sural nerve. Even with the greatest care and expertise in the surgery, the sural nerve can be traumatized simply because of its anatomical location, and not a breach of surgical care. The patient should be informed they could experience complete, permanent numbness along the dorsal lateral aspect of their foot, burning sensations, and even the development of complex regional pain syndrome, though this is extremely rare. Severe injury to the Sural nerve is rare, but it is not uncommon for the patient to experience some minor sural nerve irritation after this technique. This can result from several causes. First, even with careful placement of the obturator/cannula, the nerve can become contused, as there is anatomically limited subcutaneous tissue in some patients. Secondly, the patient may experience a traction neuropathy after they gain a normal amount of dorsiflexion, that prior to the surgery they never had. This can place the sural nerve into a "traction", which may cause temporary symptoms 3-6 weeks after the surgery.

## ENDOSCOPIC GASTROCNEMIUS RECESSON SURGICAL TECHNIQUE:

As with any endoscopic technique, proper placement of the surgical instrumentation is imperative to success. Hemostasis is achieved with a thigh tourniquet and preparation and draping are according to standard operative protocol. The EGR technique can be performed with either epidural or general anesthesia. If the patient is in a supine position, the leg should be elevated by a surgical assistant, while appropriate anatomical topography is mapped out. One of the areas of most confusion with this technique is at what level to transect the Gastrocnemius aponeurosis. Unfortunately, there is no one universal measurement that works for every patient.

The author recommends that the surgeon position the cannula at the mid endoscopic zone. The mid endoscopic zone in our 55 cadaveric studies ranged from 16.40cm to 17cm. This measurement is made from the calcaneal insertion of the Achilles tendon proximal. The surgeon must always correlate these measurements with palpable anatomy. A second method for locating proper cannula placement is to palpate distal to proximal along the Achilles tendon and note where it begins to "fan" out into of the gastrocnemius. 3-4cm above this fanning area is a good level for placement of the cannula as well.

Once the mid-endoscopic zone measurement is ascertained, the surgeon should identify the approximate location of the sural nerve, for proper planning of the medial and lateral portal incisions. From the center point of the popliteal fossa, between the two heads of the Gastrocnemius, a point is made with the skin marker. Another point, 1 cm posterior to the lateral malleolus, at the level of the ankle joint is made. A line drawn between these two points will represent the course of the sural nerve[5]. Once this has been mapped out, (Fig 1) determine the location of your medial portal.

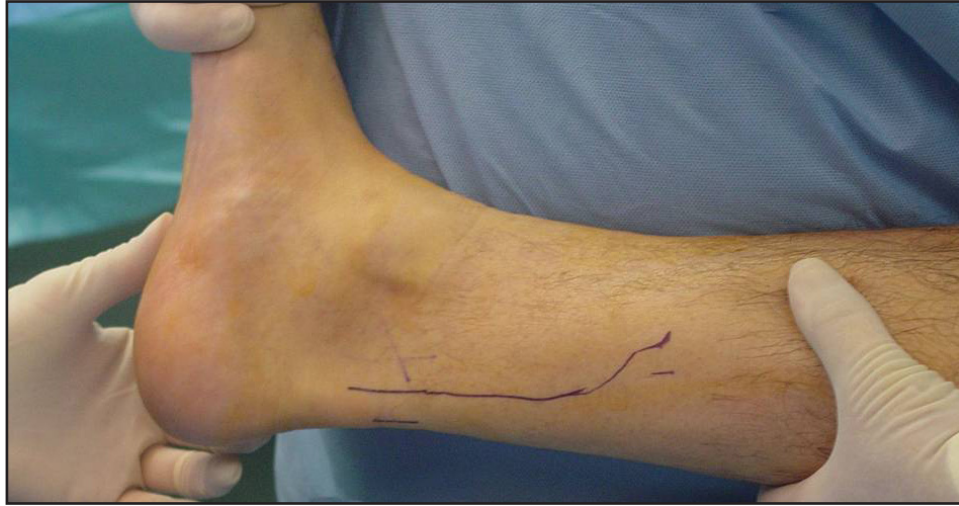

Fig 1

Currently, it is recommended that the medial portal be made first, as this allows for better access to the medial head of the gastrocnemius aponeurosis, which when released can allow for normal dorsiflexion without cutting the lateral portion. This is measured intraoperatively, and in many occasions the amount of aponeurosis cut is less than two-thirds. If there is still not enough dorsiflexion with this amount of release, then more lateral aponeurosis should be cut.

On the medial aspect of the calf (lateral is optional), use your thumb to palpate anteriorly locating where the gastrocnemius “falls” off or ends. At this location a 1cm incision is made vertically level with your mid-endoscopic zone measurement.

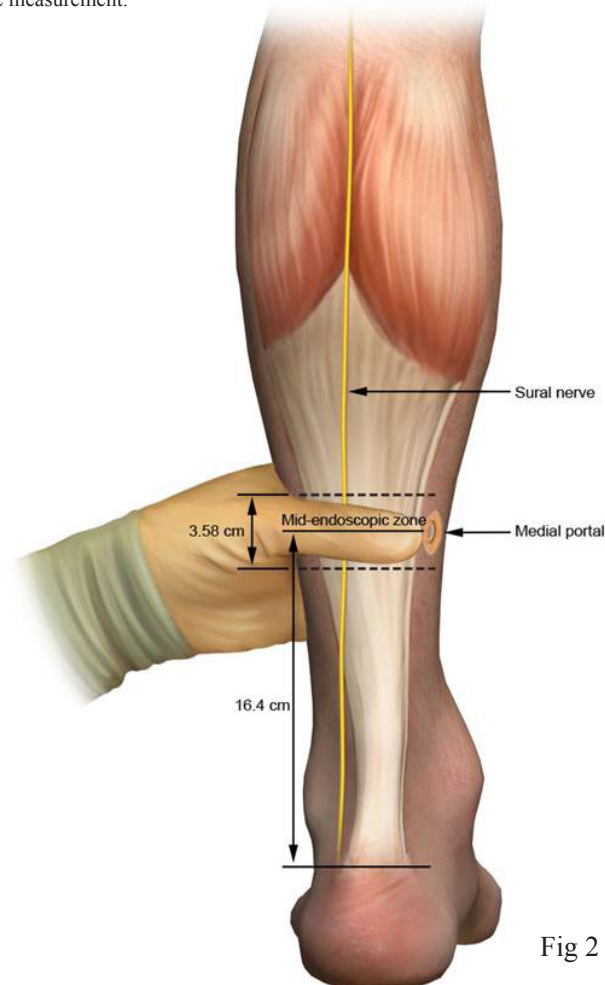


Fig 2

The scalpel blade should not be buried, and the incision carried only through the dermis. Blunt dissection is then completed with Steven's tenotomy scissors through the subcutaneous fat, down to the layer of the deep crural fascia. This is easily palpated with the tips of the scissors. It is at this point that the sural nerve is protected via careful separation of the subcutaneous tissues (where the sural nerve is now coursing), and the deep fascia of the leg. Fig 3

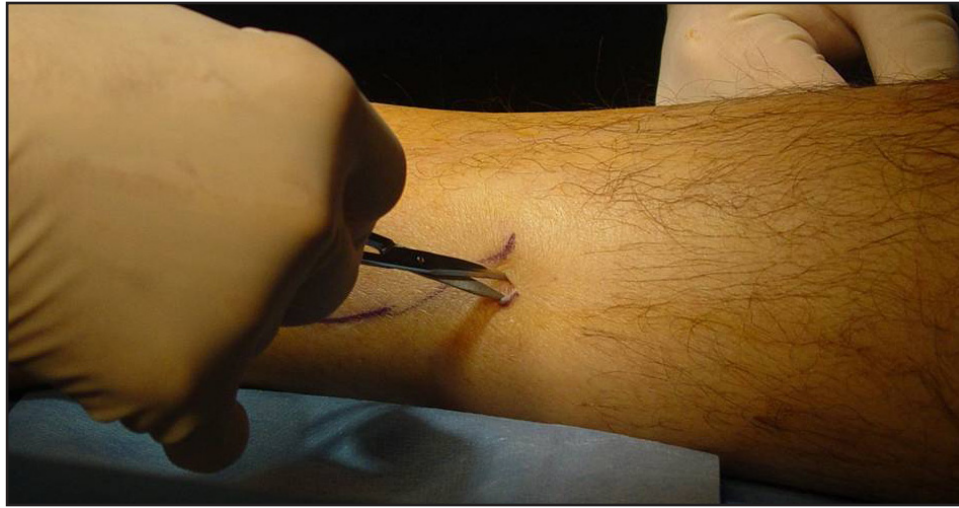


Fig 3

Using the fascial elevator, separate the subcutaneous fat from the posterior aspect of the gastrocnemius. Pass the fascial elevator completely across tenting the tissue of the lateral aspect. There should be minimal resistance; if resistance is met, redirect your elevator Fig 4. Remove the elevator and insert the obturator /cannula assembly in the same plane. Gently apply anterior pressure while passing the obturator cannula assembly laterally, once the tip of the obturator is palpated on the lateral aspect, a small incision is made over the tip to allow exposure of the cannula through the skin. It is important to avoid placement of the obturator cannula assembly too distal, this may not allow adequate lengthening of the triceps surae.

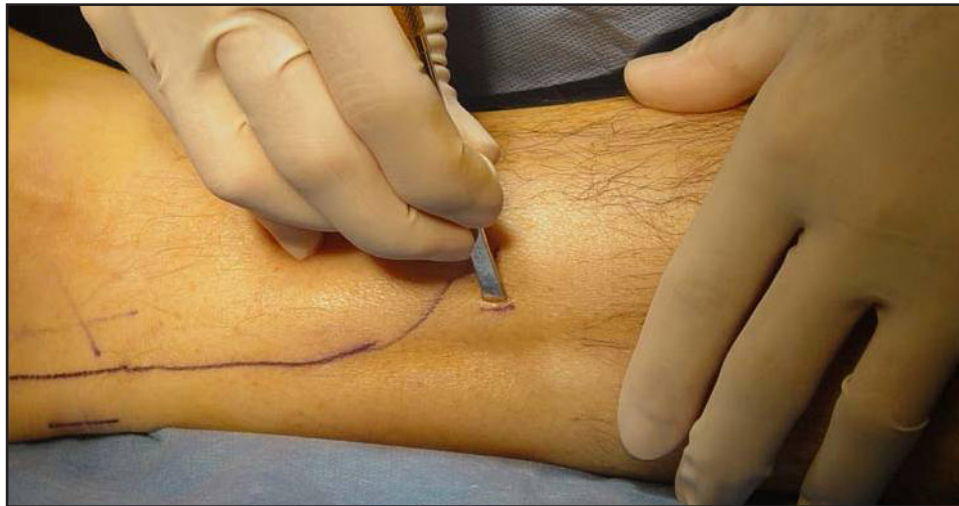

Fig 4

We recently completed an anatomical study of the posterior calf to measure the gastrocnemius aponeurosis to ascertain measurements that may aid in the pre-operative planning and instrumentation placement. The following was found:

Endoscopic Zone (cm)				
	Right (R) (n=28)	Left (L) (n=27)*	R & L (n=55)	Intracadaveric Variation (n=27)
Mean	3.61	3.57	3.59	0.54
Mode	3	3	3	0
SD	1.31	0.91	1.12	0.93
Min	2	2	2	0
Max	8	6	8	3
Calcaneus to Mid-Endoscopic Zone (cm)				
	Right (R) (n=28)	Left (L) (n=27)*	R & L (n=55)	Intracadaveric Variation (n=27)
Mean	16.3	16.5	16.4	0.93
Mode	16	17	17	0
SD	1.95	1.94	1.93	1.27
Min	12	13	12	0
Max	22	23	23	5

\*One cadaveric specimen was missing the left Gastrocnemius muscle and aponeurosis due to prior dissection.

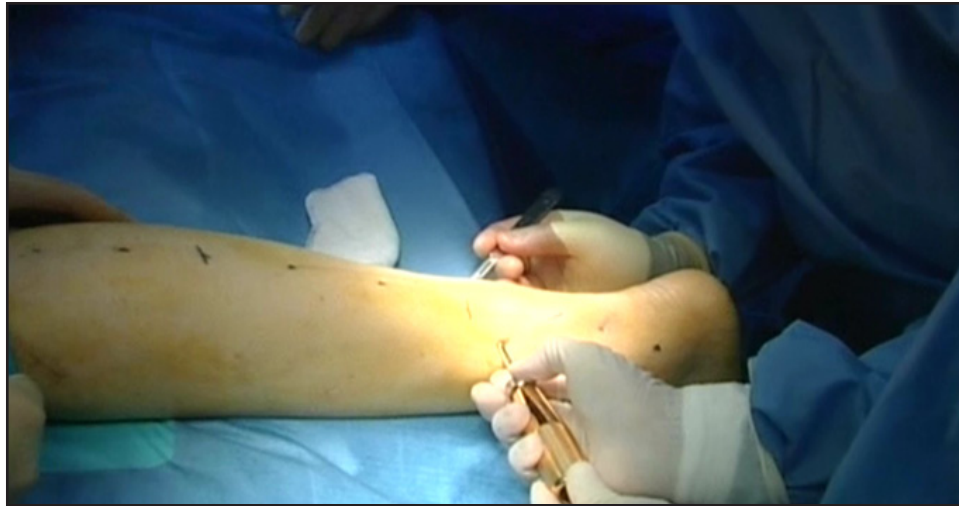

Fig 5

The surgical assistant can then make a small incision over the tip of the obturator, which will allow for passage of the instrumentation through the leg. (Fig 5)

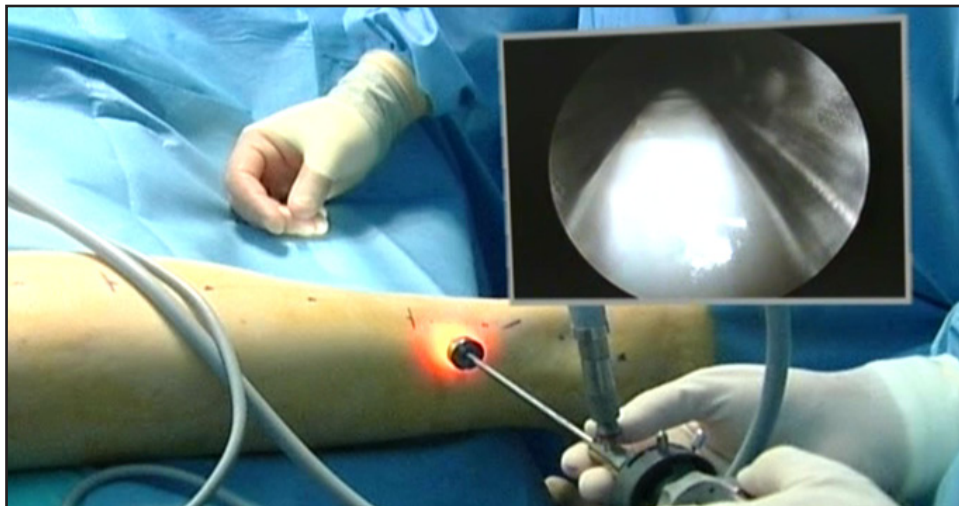


Fig 6

Photo shows placement of 4.0 mm scope in medial portal with inset photo of gastrocnemius.

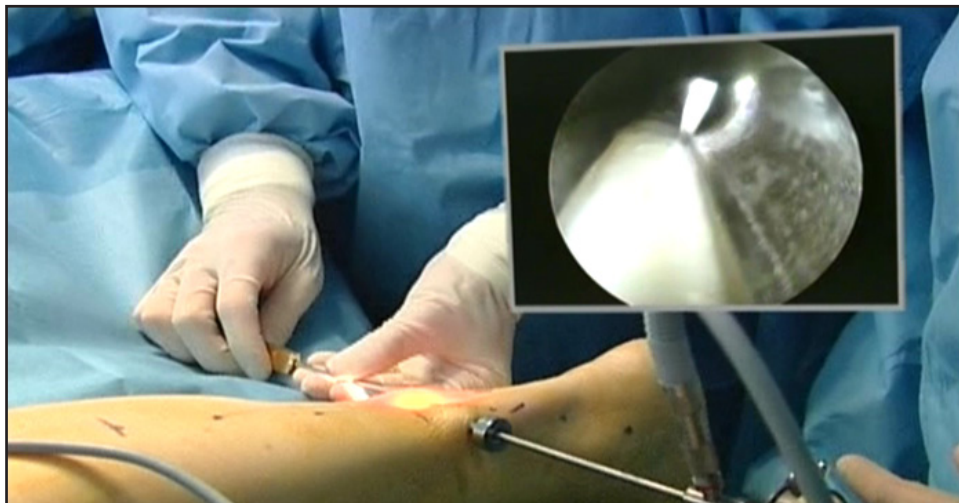


Fig 7

The inset picture shows the knife coming into view, preparing to make the cut through the gastrocnemius aponeurosis.

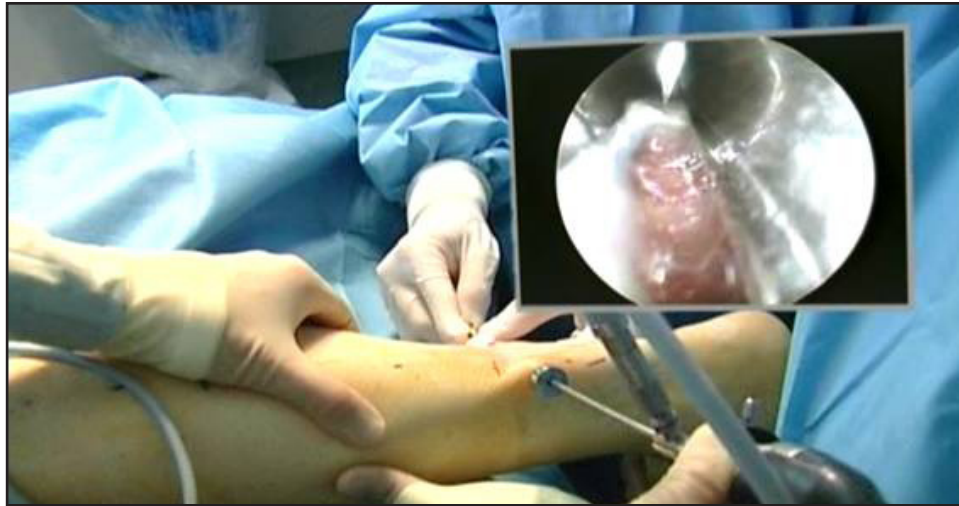

Fig 8

The inset picture illustrates how well the fibers of the muscle belly beneath the aponeurosis can be visualized, which is nicely separated, and also shows that even under magnification, there has been no damage to the muscular tissue.

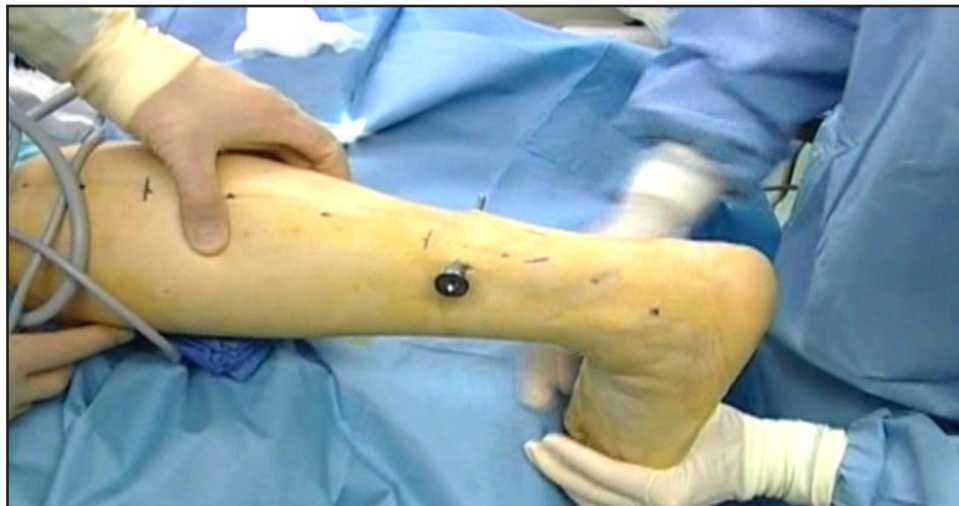

Fig 9

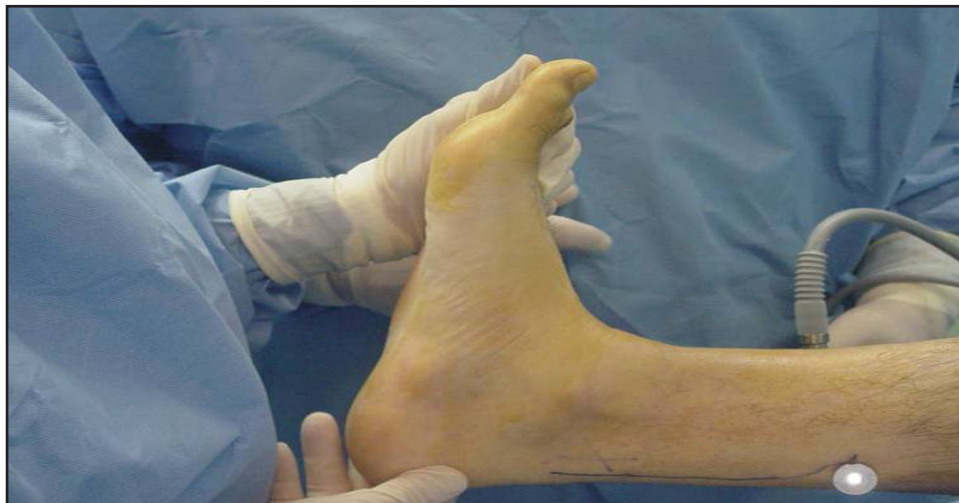

Fig 10

The increase in dorsiflexion is usually dramatic at this stage of the procedure. This has been documented by other authors as well.[6] This is seen in the above intraoperative photos.

## POST OPERATIVE MANAGEMENT:

When performed in conjunction with other surgical procedures, the EGR patient must be managed post-operatively in accordance with the demands of the other procedures, but there are situations where surgeries should be staged for maximizing outcomes. Interestingly, many planned forefoot surgeries are not needed after several months post-op EGR, with improvement in biomechanics many pathologic conditions become asymptomatic. An example of this is Morton's entrapment. A very light compression dressing is all that is needed. These patients should, however, be kept at a minimum of 0 degrees dorsiflexion for the first 4 weeks. In EGR cases without other surgical procedures performed concurrently the patient is allowed to walk immediately in a below the knee removable walking boot. Patients are advised to remove their surgical boot the day of surgery and move their ankle actively and passively to decrease the chance of developing a DVT. They are encouraged to do some gentle gastroc stretching during the first 4 weeks, with the knee extended. It is also recommended that these patients remain in the boot for the first 4 weeks, followed by 4 more weeks of guarded activity. Somewhere between 8-12 weeks, the patients who have undergone isolated EGR can usually resume full athletic activity. Some patients may experience weakness for up to one year after the procedure. Sutures can be removed 10-14 days after the surgery. They are allowed to shower for less than 5 minutes, without immersion, the day after surgery. The small incisions are then covered with a band-aid.

## DISCUSSION:

It is the author's belief that while the operating surgeon is frequently aware of the presence of equinus in the patient demonstrating forefoot nerve entrapment symptomatology, as well as other common conditions, the pathomechanics of equinus is rarely addressed surgically in these cases for several reasons. Previously, more invasive techniques, such as open Gastrocnemius recessions, and tendo Achilles lengthening required longer operative times, increasing periods of post-operative morbidity for the patient. Endoscopic gastroc recession is minimally invasive, requires very little intraoperative time, and is minimally painful after surgery. The technique seems to be well accepted by the patient, especially those who have previously had another procedure like a tendo Achilles lengthening on the contralateral side. In the panoply of complex pedal conditions requiring surgical intervention, EGR offers an additional technique to enhance patient surgical outcomes.

Consideration of equinus should be at the forefront of the surgeon's decision-making process when planning routine forefoot procedures ranging from Hallux Valgus reconstruction to decompression of forefoot nerve entrapments. With addition of the EGR technique to the surgeon's armamentarium, foot surgery outcomes can be expected to improve. The procedure, while precise, is not difficult after appropriate training. This technique should also be implemented in diabetic patients with forefoot ulceration and pathology. As can be seen below with the pre and post-operative F-scans, a significant reduction in forefoot plantar pressure is attained after EGR.

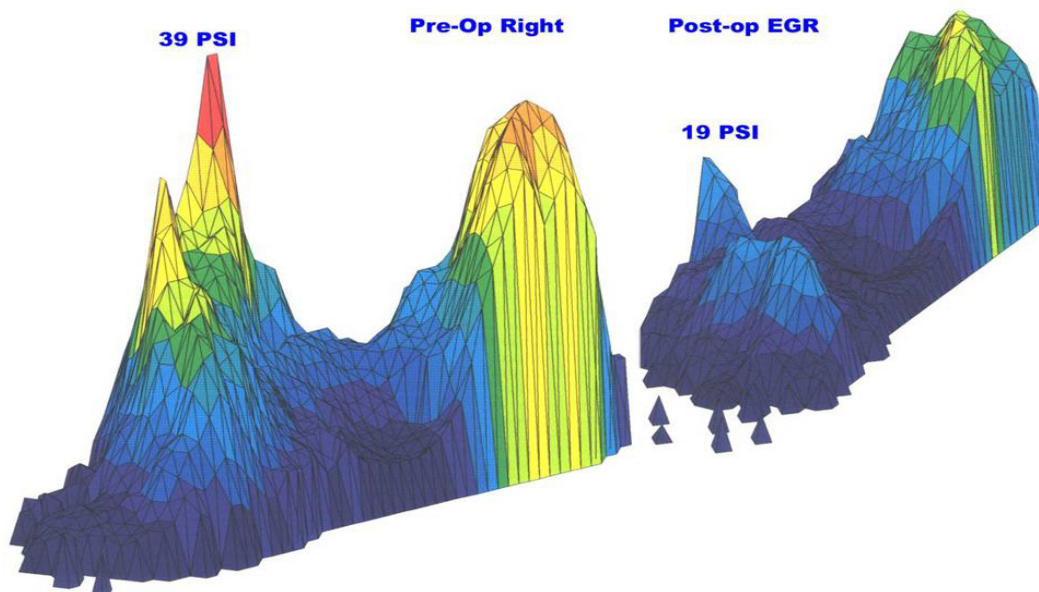


Fig 11

Pre-operative and post-operative F-scan computerized plantar pressure measurements at mid-stance phase of gait, demonstrating a reduction in forefoot pressure from 39 psi to 19 psi. This is a 49% reduction in pressure.

## REFERENCES:

1. Lavery, L.A., D.G. Armstrong, and A.J. Boulton, Ankle equinus deformity and its relationship to high plantar pressure in a large population with diabetes mellitus. *J Am Podiatr Med Assoc*, 2002. 92(9): p. 479-82.
2. Sgarlato, T.E., *A Compendium of Podiatric Biomechanics*. 1971.
3. Sgarlato, T.E., Medial gastrocnemius tenotomy to assist body posture balancing. *J Foot Ankle Surg*, 1998. 37(6): p. 546-7.
4. Sgarlato, T.E., et al., Tendo achillis lengthening and its effect on foot disorders. *J Am Podiatry Assoc*, 1975. 65(9): p. 849-71.
5. Singh, S., Naasan, A., Use of Distally Based Superficial Sural Island Artery Flaps in Acute Open Fractures of the Lower Leg. *Annals of Plastic Surgery*, 2001. 47(Number 5): p. 505-510.
6. Saxena, A. and A. Widtfeldt, Endoscopic gastrocnemius recession: Preliminary report on 18 cases. *J Foot Ankle Surg*, 2004. 43(5): p. 302-6.